

Case Report

A rarely seen cause for empyema: *Leuconostoc mesenteroides*

Hanife Usta-Atmaca¹, Feray Akbas¹, Yesim Karagoz², Mehmet Emin Piskinpasa¹

¹ Internal Medicine Clinic Istanbul Education and Research Hospital, Istanbul, Turkey

² Radiology Clinic, Istanbul Education and Research Hospital, Istanbul, Turkey

Abstract

Leuconostoc species are Gram-positive, non-motile, vancomycin-resistant bacteria placed within the family of Streptococcaceae. They naturally exist in food and are important in the sauerkraut, milk and wine industries due to their role in fermentation. Infections caused by *Leuconostocs* are generally reported in immunosuppressed patients with an underlying disease, or in those who were previously treated with vancomycin. Central venous catheter insertion is also a risk factor for introducing bacteria into the body. Although they are resistant to vancomycin, leuconostocs are sensitive to erythromycin and clindamycin. Here, we report a case with pleural empyema due to *Leuconostoc mesenteroides* in an otherwise healthy person whose occupation is known to be selling pickles.

Key words: *Leuconostoc mesenteroides*; pleural empyema; pickle.

J Infect Dev Ctries 2015; 9(4):425-427. doi:10.3855/jidc.5237

(Received 02 May 2014 – Accepted 17 November 2014)

Copyright © 2015 Usta-Atmaca *et al.* This is an open-access article distributed under the Creative Commons Attribution License, which permits unrestricted use, distribution, and reproduction in any medium, provided the original work is properly cited.

Case Report

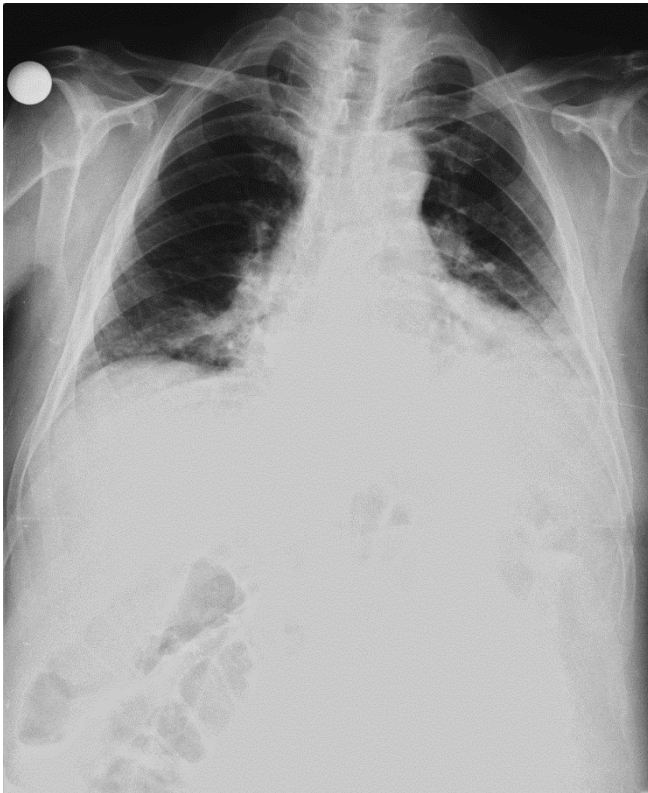
A 64 year-old male patient was admitted to our hospital with cough, fever and yellowish sputum production which had been present for the previous two weeks. He was producing and selling sauerkraut and other pickled vegetables and was otherwise completely healthy before that time. He did not have a history of smoking, alcohol consumption or receiving any chronic medication.

In his physical examination there were no pathological findings other than the reduction of pulmonary sounds in the lower 1/3 part of the left lung in thoracic auscultation. His axillary temperature was 36°C. Peripheral blood count was as follows, leukocyte: 5500/mm³ (neutrophil 65%, lymphocyte 30%), platelet: 287000/mm³, hematocrit 28%.

Biochemical tests resulted normal and serum C-reactive protein (CRP) level was 11,7 mg/dl (N:0-0.8). The homogenous opacity seen in his chest X-ray (Figure 1) in the middle and lower parts of the left lung was considered to be pleural effusion. Pleural ponction was performed. The macroscopic appearance of pleural fluid was pus and a high concentration of leukocytes was present in the microscopic evaluation. LDH level of pleural fluid was 650 U/L and albumin level was 1,5 gr/dl. Serum levels of albumin were 2 gr/dl and LDH level was 700 u/l when examined concomitantly. Blood samples which were collected

with aseptic technique were injected to BACTEC medium bottles and incubated under normal atmospheric conditions, at 35°C in automatic BACTEC blood culture machine (Becton Dickinson, Franklin Lakes, USA). The media were monitored for 7 days and the bottle showing positive was Gram-stained and subbed onto 5% sheep blood agar (Salubris, Istanbul, Turkey) and Mc Conkey agar and then was incubated at 37°C for 24 hours. Conventional methods (colony morphology on the plate surface, features of Gram staining, catalase test, coagulase test, glucose and lactose fermentation, urease presence, citrate usage, indol formation, oxidase test) and VITEK 2 Compact System (BioMérieux, Marcy L'Etoile, France) automatic identification system were used for identification of microorganisms isolated. Gram-positive cocci and high concentration of leukocytes were seen in gram-staining. In the culture *Leuconostoc mesenteroides* was grown. Computed tomography of thorax showed pleural effusion in the lower part of the left lung, thickening of the pleural membranes in this area and a consolidation containing air bronchogram in the lower lobe. The patient was diagnosed with pleural empyema based on these findings and drainage treatment with thorax tube and 2 grams of ceftriaxon combined with 1 gr claritromycin daily were started. Symptoms regression began on the fourth day of the treatment. On the fourteenth day, the

Figure 1. Homogenous opacity in the middle and lower parts of left lung.



CRP level returned to normal and the treatment was stopped at the end of the twenty-first day.

Discussion

Leuconostocs are members of the Streptococcaceae family and have only recently been recognized as potential pathogens. Bacteria is found naturally in plants and vegetables. They have economical importance due to usage in the milk and pickle industries and wine production [1].

Infections by *Leuconostoc* species are uncommon, and usually affect patients with an underlying disease, or those fitted with a venous catheter or subjects previously treated with vancomycin [2]. Bacteremia generally occur in patients hospitalized with significant underlying diseases or who had received previous antibiotic therapy. Premature birth and low birth weight are also risk factors for *Leuconostoc* sepsis [3,4]. In a high percentage of the patients from whom *Leuconostoc* was isolated; an underlined disease such as chronic renal failure, diabetes, pneumonia or chronic liver disease was reported [5]. Serious infections due to *Leuconostocs* were recently described [6]. Risk factors for *Leuconostoc* infections are immunocompromised status and indwelling

medical devices [7]. In literature; *Leuconostoc* spp was identified in blood culture in a colon adenocarcinoma patient who had surgery followed by a chemotherapy and in a catheter infection resistant to vancomycin and teicoplanin in a patient who had undergone a shunt operation due to hydrocephaly [8]. Similarly, in a patient with subarachnoid haemorrhage which was being treated with dexamethasone and lumbar punctures, *Leuconostoc* spp was isolated from cerebrospinal fluid as nosocomial meningitis cause, on the ninth day of the treatment [9]. *Leuconostoc* infections were reported in patients with liver transplantation and stem cell transplantation [10]. *Leuconostoc mesenteroides* was isolated from prosthetic valve endocarditis patients as the causative agent [11,12]. A pleural empyema case, successfully treated with clindamycin, was reported from Israel [2]. *Leuconostocs* were found in blood cultures of pediatric patients who had parenteral nutrition via central venous catheter due to short bowel syndrome [13]. *Leuconostoc* spp should be considered when vancomycin-resistant organisms resembling streptococci are isolated from blood cultures [14].

Organisms play a role in the fermentation of milk, wine and pickles. While an underlying factor is needed for those organisms to become pathogenic, in our case the patient was completely healthy and did not have invasive procedures previously. As the patient was selling and directly producing pickles, it was suspected that the organism could have passed directly. *Leuconostoc* spp are Gram-positive vancomycin-resistant bacteria and due to their microbiological characteristics, they can be identified as pneumococci, viridans streptococci or lactobacilli.

They are distinguished from other streptococci and similar bacteria by their feature of converting glucose into gas in Mann, Rogosa and Sharpe (MRS) bacterial growth medium [1].

Increase in hospital infections and *Staphylococcus* infections and methicilline resistance in those infections caused an increase in vancomycin usage for treatment. In vancomycin-resistant organisms, infections caused by staphylococci, enterococci and lactobacillus are more common. As bacteria from the streptococci family are present in the skin flora, contamination might occur if a blood culture is collected without a previous skin disinfection. There is a good response to penicillin and clindamycin treatment [15].

This case indicated that; *Leuconostoc mesenteroides* should be considered as a causative agent in community-acquired infections, also in non-

immunocompromised patients. As a direct contamination with the bacteria seems to be possible in certain industries like milk, wine and pickles, the occupation of the patient should be considered as a determinant of the possible causes.

References

1. Winn WC Jr, Allen SD and Janda W (2006) The gram positive cocci. Koneman's Color Atlas and Textbook of Diagnostic Microbiology, 6th edition. Baltimore: Lippincott Williams & Wilkins 706 p.
2. Borer A, Weber G, LS Avnon, Riesenber K, Alkan M (1997) Pleural Empyema Caused by *Leuconostoc* spp. *J Infect Dis* 29 Suppl 3: 311-312.
3. Janow G, Lambert B, Scheiner M, Rosen O, Goldman DL, Soghier L (2009) *Leuconostoc* septicemia in a preterm neonate on vancomycin therapy: case report and literature review. *Amer J Perinatol* 26 Suppl 1: 89-91.
4. Yossuck P, Miller-Canfield P, Moffett K, Graeber J (2009) *Leuconostoc* spp sepsis in an extremely low birth weight infant: a case report and review of the literature. *W V Med J* 105 Suppl 5: 24-27.
5. Ling ML (1992) *Leuconostoc* Bacteraemia. *Singapore Med J* 33: 241-243.
6. Swenson JM, Facklam RR, Thornsberr C (1990) Antimicrobial susceptibility of vancomycin-resistant *Leuconostoc*, *Pediococcus* and *Lactobacillus*. *Antimicrob Agents Chemother* 34 Suppl 4: 543-549.
7. Gillespie RS, Symons MJ, McDonald RA (2002) Peritonitis due to *leuconostoc* species in a child receiving peritoneal dialysis. *Pediatr Nephrol* 17: 966-968.
8. Aygun H, Bozkurt GY, Memikoglu O, Cokca F (2005) Case report: two *Leuconostoc* bacteremia cases. *Mikrobiyol Bul* 39 Suppl 2: 225-228.
9. Hatipoglu CA, Yildiz E, Koktekir E, Ipekkar K, Karakoc EA, Demiroz AP (2008) A case of vancomycin resistant *leuconostoc* meningitis. *Mikrobiyol Bul* 42 Suppl 4: 695-699.
10. Tholpady SS, Sifri CD, Sawyer RG, Hazen KC, Pruet TL, Bonatti H (2010) *Leuconostoc pseudomesenteroides* blood stream infection following liver transplantation. *Ann Transplant* 15 Suppl 1: 61-66.
11. Vazquez E, Carazo I, Martin A, Lozano C, Cuesta I, Pagola C (1998) Infectious endocarditis caused by *Leuconostoc mesenteroides*. *Enferm Infecc Microbiol Clin* 5: 237-238.
12. Starr AJ (2007) *Leuconostoc* Species-Associated Endocarditis. *Pharmacotherapy* 27 Suppl 5: 766-770.
13. Florescu D, Hill L, Sudan D, Iwen PC (2008) *Leuconostoc* bacteremia in pediatric patients with short bowel syndrome: case series and review. *Pediatr Infect Dis J* 11: 1013-1019.
14. Bernaldo de Quirós JCL, Muñoz P, Cercenado E, Hernandez Sampelayo T, Moreno S and Bouza E (1991) *Leuconostoc* species as a cause of bacteremia: Two case reports and a literature review. *EJCMID* 10 Suppl 6: 505-509.
15. Handwerger S, Horowitz H, Coburn K, Kolokathis A, Wormser GP (1990) Infection Due to *Leuconostoc* Species: Six Cases and Review. *Clin Infect Dis* 12 Suppl 4: 602-610.

Corresponding author

Dr Hanife Usta-Atmaca
Kasap Iyas Mah. Org. Abdurrahman Nafiz Gürman Cd. PK: 34098
Fatih/Istanbul-Turkey
Phone: +9002124596000
Fax: +902126320060
Email: hanifeusta@yahoo.com

Conflict of interests: No conflict of interests is declared.