

Liver Abscesses in Feedlot Cattle: A Review^{1,2}

T. G. Nagaraja^{*,3} and M. M. Chengappa[†]

Departments of ^{*}Animal Sciences and [†]Diagnostic Medicine and Pathobiology,
Kansas State University, Manhattan 66506

ABSTRACT: Liver abscesses in slaughtered beef cattle result from aggressive grain-feeding programs. The incidence, averaging from 12 to 32% in most feedlots, is influenced by a number of dietary and management factors. Liver abscesses represent a major economic liability to producers, packers, and ultimately consumers. Besides liver condemnation, economic impacts include reduced feed intake, reduced weight gain, decreased feed efficiency, and decreased carcass yield. *Fusobacterium necrophorum*, a member of the ruminal anaerobic bacterial flora, is the primary etiologic agent. *Actinomyces pyogenes* is the second most frequently isolated pathogen. Ruminal lesions resulting from acidosis generally are accepted as the predisposing factors for liver abscesses. *F. necrophorum* possesses or produces a number of virulence factors that participate in the penetration and coloni-

zation of the ruminal epithelium and subsequent entry and establishment of infection in the liver. However, only a few virulence factors have been characterized well. Control of liver abscesses in feedlot cattle generally has depended on the use of antimicrobial compounds. Five antibiotics (i.e., bacitracin methylene disalicylate, chlortetracycline, oxytetracycline, tylosin, and virginiamycin) are approved for prevention of liver abscesses in feedlot cattle. Tylosin is the most effective and the most commonly used feed additive. Tylosin feeding reduces abscess incidence by 40 to 70%. The mode of action of antibiotics in preventing liver abscesses is believed to be via inhibition of ruminal *F. necrophorum*. Protective immunity against *F. necrophorum* induced by a variety of antigenic components has ranged from ineffectual to significant protection.

Key Words: Feedlots, Liver Abscesses, *Fusobacterium necrophorum*, Rumen, Antibiotics, Vaccines

©1998 American Society of Animal Science. All rights reserved.

J. Anim. Sci. 1998. 76:287-298

Introduction

Liver abscesses can occur at all ages and in all types of cattle, including dairy cows, but they have the greatest economic importance for grain-fed cattle. Abscessed livers in slaughtered feedlot cattle are associated with an aggressive feeding program. Although liver abscesses have been reported around the world, they are most common in intensively fed beef cattle in the United States, Canada, Europe, Japan, and South Africa (Nagaraja et al., 1996a).

Liver abscesses are pus-filled, have capsules that vary in thickness, and range in size from a minute pinpoint to over 15 cm in diameter. The distribution of abscesses in the liver lobes shows no consistent pattern. Histologically, abscesses are composed of

pyogranulomatous reactions with necrotic centers composed of degenerating hepatocytes and leukocytes. The capsule layer consists of fibrocytes, collagen, and elastic fibers (Lechtenberg et al., 1988). The earliest lesion is a microabscess, possibly induced by an embolus of bacteria in the hepatic sinusoid; the lesion then progresses to coagulative necrosis by involving adjacent hepatocytes (Nakajima et al., 1986). Subsequently, the lesion gradually changes into a pus-filled, encapsulated, true abscess. Based on experimental infections in mice and cattle, the change from coagulative necrosis to abscess takes from 3 to 10 d (Jensen et al., 1954c; Abe et al., 1976b; Lechtenberg and Nagaraja, 1991). Abscesses eventually become sterile; they are replaced by fibrous scars and eventually resorbed.

Incidence

The incidence of liver abscesses in specific groups of grain-fed cattle can range from 1 or 2% to as high as 90 or 95%. Generally, the incidence averages from 12 to 32% in most feedlots (Brink et al., 1990). Wide

¹Presented at a symposium titled "Bud Britton Memorial Symposium on Metabolic Disorders of Feedlot Cattle," July 1996, following the ASAS 88th Annu. Mtg., Rapid City, SD.

²Contribution No. 97-155-J, Kansas Agric. Exp. Sta., Manhattan.

³To whom correspondence should be addressed.

Received September 30, 1996.

Accepted April 10, 1997.

variation in incidence indicates the involvement of a number of factors. Liver abscesses generally are the direct result of feeding practices; therefore, diet is probably a major factor influencing the incidence. The incidence is affected by the amount and possibly the type of roughage included in the finishing diet. Generally, the incidence and severity of abscesses increase as roughage level in the diet decreases (Harvey et al., 1968; Foster and Wood, 1970; Brent, 1976; Gill et al., 1979; Zinn and Plascienca, 1996). High roughage levels promote a more stable ruminal fermentation and decrease the variation in feed intake, thereby lowering the incidence of acidosis and rumenitis. However, some studies have reported no difference in liver abscess incidence with 0% roughage diets vs diets containing 3 to 15% roughage fed throughout the finishing phase (Kreikemeier et al., 1990; Stock et al., 1990). Besides the amount, the physical characteristics of the roughage may have an influence on the incidence of liver abscesses. Utley et al. (1973) reported that 3.7% of the steers fed 80% concentrate and 20% whole peanut hulls had liver abscesses, but when hulls were ground or pelleted, the incidence increased to 56 and 59%, respectively. Cattle fed dry hay tended to have a higher incidence of liver abscesses than cattle fed silage as the roughage source (Mader et al., 1991b, 1993). Increased feed sorting in diets containing dry roughage (compared to silage) possibly contributes to ruminal acidosis and subsequent liver abscesses. Grain type also has an influence on the incidence of liver abscesses (Hale, 1985). Grains that are categorized as "rapidly fermented," such as wheat, barley, high-moisture corn, and steam-flaked corn, promote greater fluctuations in ruminal pH and intake; this leads to acidosis, rumenitis, and, subsequently, to liver abscesses (Fulton et al., 1979; Stock et al., 1987, 1990). Grain processing, particularly gelatinization of the starch granules, increases the rate of ruminal fermentation of the starch and, therefore, increases the probability of acidosis and liver abscesses. However, evidence to link the incidence of liver abscesses to the rate of ruminal fermentation of starch is inconsistent. Stock et al. (1990) have reported a numerically higher incidence of severe abscesses (A+) with a mixture of dry-rolled corn and dry-rolled wheat compared to dry-rolled corn alone, but Ladely et al. (1995) observed a higher incidence of liver abscesses in cattle fed a corn hybrid with intermediate rate of starch fermentation than in cattle fed a hybrid with a fast rate of fermentation in the rumen. Mader et al. (1991a) reported a higher percentage of liver abscesses in cattle fed high-moisture corn than in cattle fed dry-rolled corn, but Stock et al. (1991) observed no difference between dry-rolled corn and high-moisture corn fed whole rolled or in combination with dry-rolled corn.

The incidence of liver abscesses is somewhat higher for feedlot steers than for heifers, and Holsteins have a higher incidence than beef breeds (Nagaraja et al.,

1996b). The higher incidence in Holsteins is not surprising; most Holsteins are on feed much longer, and generally they have higher feed intake than beef steers of equal starting weight (average of 12% higher; Hicks et al., 1994). Also, Holsteins may have a higher incidence of digestive upsets and deaths than beef cattle (Vogel and Parrott, 1994). A slightly higher incidence (by 1 to 2%) in steers than in heifers is believed to be related to feed intake. Steers generally consume 1 to 3% more dry matter than heifers, and heifers generally mature earlier and tend to finish earlier than steers of a comparable weight (Dehaan et al., 1995).

Because liver abscesses are secondary to acidosis and rumenitis, feeding practices such as rapidly increasing dietary energy and poor or inconsistent bunk management characterized by irregular feeding (both amounts and intervals) may prompt acidosis and rumenitis (Elam, 1976) and eventually lead to a higher incidence of liver abscesses. However, documentation linking incidence of liver abscesses to feeding practices, such as type of step-up, is lacking. Also unknown is why cattle in some pens of a particular feedlot may have a low incidence of liver abscesses whereas those in adjacent pens fed the same feed have an extremely high incidence.

Economic Importance

Liver abscesses are a major economic liability to producers, packers, and ultimately to consumers of beef. The National Beef Quality Audit (1995) indicated that liver condemnations (averaging 22.2% of slaughtered beef cattle in 1995) ranked second in a list of the top 10 concerns of the packers. Abscesses are the leading cause of liver condemnation in the United States (Figure 1; Montgomery, 1992). The liver accounts for approximately 2% (by weight) of the carcass, by itself, this is a significant financial loss. However, the greatest economic impact of liver abscesses is from reduced animal performance and carcass yield. Cattle with abscessed livers have reduced feed intake, reduced weight gain, decreased feed efficiency, and decreased carcass dressing percentage. The reported effects of abscesses on animal performance have ranged from no effect (Smith, 1944; Wieser et al., 1966; Harman et al., 1989) to a depression in daily gain of as much as 11% and a decrease in feed efficiency of up to 9.7% (Brink et al., 1990). These effects are evident primarily for cattle with the most severe abscesses (based on size and number), generally referred to as A+ (based on a scale of 0, A-, A, and A+; Brown et al., 1975); liver abscesses in the A- or A category have no measurable impact on performance. Brink et al. (1990) summarized data from 12 experiments evaluating the association of severity of liver abscesses with feed intake and feed efficiency involving 566 cattle individually

Table 1. Relationship between severity of liver abscesses and performance and carcass yields in feedlot cattle

Item	Liver abscess score ^a			
	0	A-	A	A+
Brink et al., 1990				
No. of steers	405	52	37	72
Daily feed intake, kg DM	8.39	8.27	8.42	7.96
Daily gain, kg	1.27	1.23	1.24	1.15
Gain/DM	.151	.149	.145	.130
Montgomery, 1985				
No. of steers	1,166	164	45	72
Live weight, kg	490 ^c	480 ^c	473 ^c	442 ^d
Hot carcass weight, kg	310 ^c	302 ^c	300 ^c	274 ^d
Dressing percentage	63.3 ^c	62.8 ^c	62.7 ^c	61.7 ^d
Fat thickness, cm	1.10 ^c	1.10 ^c	1.13 ^c	.98 ^d
USDA yield grade	2.54	2.46	2.47	2.40
USDA quality grade ^b	2.27	2.31	2.40	2.23
Trim due to abscesses, % of carcass wt.	.0214 ^c	.0205 ^c	.0424 ^c	.4538 ^d

^a0 = No abscesses; A- = one or two small abscesses or scars; A = two to four small, well-organized abscesses; A+ = one or more large or multiple, small, active abscesses with or without adhesions.

^bChoice = 3; Good = 2.

^{c,d}Means in the same row with different superscripts differ ($P < .05$).

fed a diet based on dry-rolled corn grain. Cattle with A+ liver scores were the only group that differed significantly from nonabscessed cattle in daily feed intake, daily gain, and gain to feed ratio (Table 1).

Cattle with severe A+ liver abscesses also may require more carcass trimming because of adhesion of abscesses to the diaphragm and surrounding organs; in some instances, condemnation of the entire viscera is necessary. This costs packers money. In a study involving commercially fed cattle from seven feedyards in the Texas Panhandle area, the dressing percentage was 1.6% higher for the group with normal livers than for the group with A+ liver abscesses (Table 1; Montgomery, 1985). Similarly, Brink et al. (1990) have documented a significant reduction in efficiency

of feed utilization calculated from hot carcass weights in cattle with A+ liver abscesses. Accidental rupture of an abscess and contamination of a carcass with pus interrupt the flow of carcasses along the chain on the slaughter floor, thus causing loss of expensive time and labor.

Etiology

Bacterial Flora. Numerous investigators have evaluated the bacterial flora, both anaerobic and aerobic, of bovine liver abscesses (Scanlan and Hathcock, 1983; Lechtenberg et al., 1988; Nagaraja et al., 1996a; Tan et al., 1996). Almost all studies have concluded that *Fusobacterium necrophorum*, previously named *Sphaerophorus necrophorus*, is the primary etiologic agent. This organism also is implicated as the primary pathogen in necrotic laryngitis (calf diphtheria), footrot, and foot abscesses in cattle (Emery et al., 1985; Tan et al., 1996). The incidence of *F. necrophorum* from cultured liver abscesses has ranged from 81 to 100% of abscesses. In some instances, the organism has been involved as a single pathogen (Berg and Scanlan, 1982; Lechtenberg et al., 1988), but often it was associated with a variety of other anaerobic and facultative bacteria (Scanlan and Hathcock, 1983). Other bacteria isolated have included *Actinomyces pyogenes*, previously named *Corynebacterium pyogenes* (Calkins and Scrivner, 1967; Calkins and Dewey, 1968; Kanoe et al., 1976, 1979; Simon and Stovell, 1971; Berg and Scanlan, 1982; Lechtenberg et al., 1988); *Bacteroides* spp. (Newsom, 1938; Simon and Stovell, 1971; Berg and Scanlan, 1982); *Clostridium* spp. (Simon and Stovell, 1971); *Pasteurella* spp.

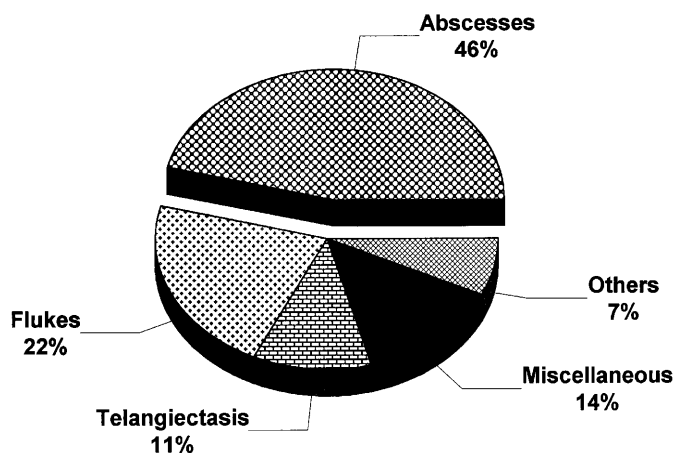


Figure 1. Leading causes of liver condemnations in slaughtered beef cattle in the United States (Montgomery, 1992).

Table 2. Bacterial flora of liver abscesses from grain-fed cattle

Reference	No. of livers examined	No. of abscesses cultured	Bacteria					Other bacteria, %
			<i>Fusobacterium necrophorum</i>				<i>Actinomyces pyogenes</i> , %	
			<i>Fusobacterium necrophorum</i> , %	<i>F. necrophorum</i> as pure culture, %	subsp. <i>necrophorum</i> (Type A), %	subsp. <i>funduliforme</i> (Type B), %		
Newsom, 1938	100	100	96	85	ND ^b	ND	2	1
Yamamoto, 1938	18	18	94	83	ND	ND	0	NS
Madin, 1949	55	109	85	68	ND	ND	—	11
Fiévez, 1963	117	320	81	71	69	6	NS	10
Aalbaek, 1971	NS ^a	16	100	75	75	25	NS	NS
Simon and Stovell, 1971	400	431	97	67	ND	ND	16	2
Hussein and Shigidi, 1974	100	100	84	57	ND	ND	—	13
Berg and Scanlan, 1982	119	124	99	47	71	29	50	0
Lechtenberg et al., 1988	28	49	100	47	57	47	35	6
Nagaraja et al., 1993	41	41	100	31	100	15	10	29

^aNS = Not stated.

^bND = Not determined.

(Simon and Stovell, 1971); *Peptostreptococcus* spp. (Kanoë et al., 1979; Berg and Scanlan, 1982); *Staphylococcus* spp. (Kanoë et al., 1976; Berg and Scanlan, 1982; Lechtenberg et al., 1988); *Streptococcus* spp. (Madin, 1949; Calkins and Dewey, 1968; Simon and Stovell, 1971; Lechtenberg et al., 1988), and a variety of unidentified Gram-positive and Gram-negative bacteria. Table 2 shows a summary of the bacterial flora of liver abscesses from grain-fed cattle. In most situations, *A. pyogenes* is the second most frequent pathogen isolated from liver abscesses (Figure 2; Berg and Scanlan, 1982; Lechtenberg et al., 1988). The origin of *A. pyogenes* and its pathogenic mechanism are not well understood, but evidence exists for pathogenic synergy between *A. pyogenes* and *F. necrophorum* (Roberts, 1967a,b; Takeuchi, 1983).

Characteristics of *F. necrophorum*. *F. necrophorum* was recognized as an animal pathogen in the late 1880s. It is a Gram-negative, nonmotile, nonsporulating, rod-shaped (pleomorphic) bacterium (Langworth, 1977). The organism is anaerobic; the optimal redox potential of the culture medium for growth is in the range of -230 to -280 mV (Tan et al., 1992). This species generally does not ferment any carbohydrates, although some strains ferment glucose weakly; its major energy substrate is lactic acid, which is fermented mainly to acetate, butyrate, and small amounts of propionate (Lechtenberg et al., 1988). It also produces a number of proteases (Nakagaki et al., 1991; Tan et al., 1994c).

Historically, *F. necrophorum* is classified into four biotypes/biovars: A, B, AB, and C (Langworth, 1977). Biotype C is an avirulent type that has been reclassified as a new species, *Fusobacterium pseudonecrophorum* (Shinjo et al., 1990). Biotypes A and

B, the most frequent types encountered in liver abscesses, have been assigned subspecies status: subsp. *necrophorum* and subsp. *funduliforme*, respectively (Shinjo et al., 1991). Biotype AB, isolated most frequently from foot lesions of cattle and sheep (Emery et al., 1985), is encountered rarely in liver abscesses (Berg and Scanlan, 1982). Its characteristics are intermediate to those of biotypes A and B (Scanlan et al., 1986). A phylogenetic analysis using the 16s rRNA gene sequences revealed a closer relationship of biotype AB to *F. necrophorum* subsp. *funduliforme* than to subsp. *necrophorum* (Nicholson et al., 1994). The two subspecies differ in morphology, growth patterns, and biochemical and biological

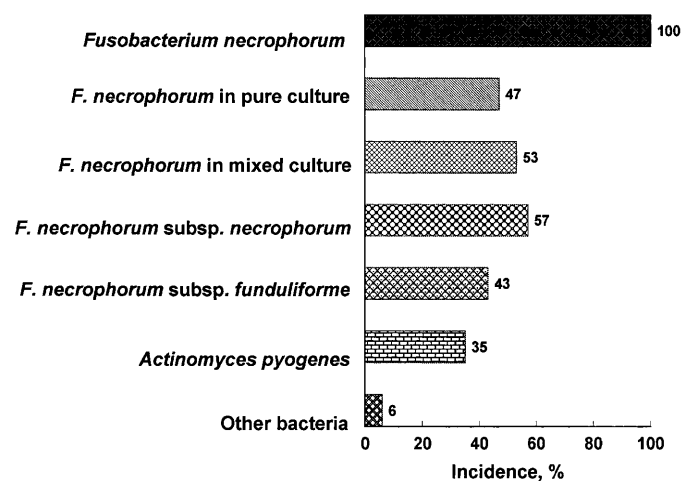


Figure 2. Bacterial flora of liver abscesses (49 abscesses from 28 livers) from feedlot cattle (Lechtenberg et al., 1988).

characteristics (Tan et al., 1994b; Nagaraja et al., 1996a). Among the biological characteristics, toxin production and virulence are of relevance to their involvement in liver abscesses (Emery et al., 1986b; Tan et al., 1996). *F. necrophorum* subsp. *necrophorum* has been isolated from 71 to 95% of liver abscesses, usually as a pure culture (up to 75%); subsp. *funduliforme* has been recovered from 5 to 29%, and only rarely as a pure culture (up to 22%; Figure 3; Lechtenberg et al., 1988). This difference in the incidence of the two subspecies reflects differences in virulence and virulence factors.

Virulence Factors of *F. necrophorum*. Several toxins have been implicated as virulence factors in the pathogenesis of *F. necrophorum* infections (Tan et al., 1996). These include leukotoxin (Roberts, 1967a,b; Coyle-Dennis and Lauerman, 1978; Scanlan et al., 1986; Tan et al., 1992, 1994b,d); endotoxic lipopolysaccharide (Garcia et al., 1975b; Warner et al., 1975; Inoue et al., 1985); hemolysin (Kanoe et al., 1984; Amoako et al., 1994; Tan et al., 1994b); hemagglutinin (Kanoe and Iwaki, 1986, 1987); capsule (Brook and Walker, 1986; Emery, 1989; Garcia et al., 1992); adhesions or pili (Miyazato et al., 1978; Nagai et al., 1984; Emery, 1989; Shinjo and Kiyoyama, 1986); platelet aggregation factor (Forrester et al., 1985; Kanoe and Yamanaka, 1989); dermonecrotic toxin (Kanoe et al., 1995); and a number of extracellular enzymes including proteases and deoxyribonuclease (Nakagaki et al., 1991; Amoako et al., 1993; Tan et al., 1994b). Among these factors, leukotoxin and endotoxic lipopolysaccharide have been investigated extensively and are believed to be the major virulence factors involved in fusobacterial infection (Emery et al., 1986b; Tan et al., 1996). The importance of leukotoxin to the infectivity of *F. necrophorum* is evidenced by correlation between toxin production and ability to induce abscesses in laboratory animals (Coyle-Dennis and Lauerman, 1979; Emery et al., 1986b) and the inability of nonleukotoxin-producing strains to induce foot abscesses in cattle following intradermal inoculation (Emery et al., 1985).

The difference in virulence between the two subspecies is attributed to the difference in the quantity and composition of lipopolysaccharide and in the amount of leukotoxin produced (Berg and Scanlan, 1982; Inoue et al., 1985; Scanlan et al., 1986; Tan et al., 1992). Several investigators have reported that leukotoxin production is higher by subsp. *necrophorum* than by subsp. *funduliforme* (Berg and Scanlan, 1982; Scanlan et al., 1986; Tan et al., 1992).

***Fusobacterium necrophorum* in the Rumen.** *F. necrophorum* is a normal inhabitant of the gastrointestinal tract of mammals (Langworth, 1977). It has been isolated from ruminal contents of cattle fed a variety of diets (Robinson et al., 1951; Garcia et al., 1971; Kanoe et al., 1978; Wada, 1978; Berg and

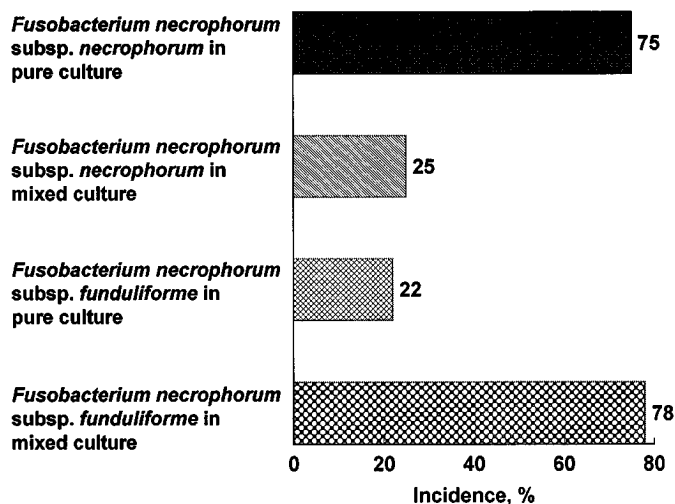


Figure 3. Incidence of the two subspecies of *Fusobacterium necrophorum* (subsp. *necrophorum* and *funduliforme*) in liver abscesses of feedlot cattle (Lechtenberg et al., 1988).

Scanlan, 1982; Tan et al., 1994b). The concentration in the rumen is in the range of 10^5 to 10^6 /g of ruminal contents. However, this concentration is influenced by the diet. The number of *F. necrophorum* cells in the rumen increased after the diet was changed from roughage (7×10^5 /g) to high-grain (3 to 7×10^6 /g; Tan et al., 1994c). Because *F. necrophorum* uses lactate as the major substrate and not any sugars, the increased population in cattle fed the high-grain diet probably was due to an increased lactate availability in the rumen. *F. necrophorum* also is isolated frequently from ruminal walls exhibiting parakeratosis and rumenitis and less frequently from unaffected ruminal epithelium (Kanoe et al., 1978).

Pathogenesis

Liver abscesses are secondary to the primary foci of infection in the ruminal wall. Smith (1944) was the first to observe a relationship between ulcerative lesions of the rumen and liver abscesses in feedlot cattle. Subsequently, Jensen et al. (1954a,b) confirmed this relationship, reported a high correlation for the occurrence of liver abscesses and ruminal pathology, and proposed the term "rumenitis—liver abscess complex" (Figure 4). However, Weiser et al. (1966) detected no correlation between incidence of liver abscesses and ruminal lesions. Although the precise pathogenic mechanism is not recognized, it is well accepted that ruminal lesions resulting from acidosis are the predisposing factors for hepatic abscesses (Jensen et al., 1954b). Acid-induced rumenitis and damage of the protective surface usually are associated with a sudden change to high-energy diets

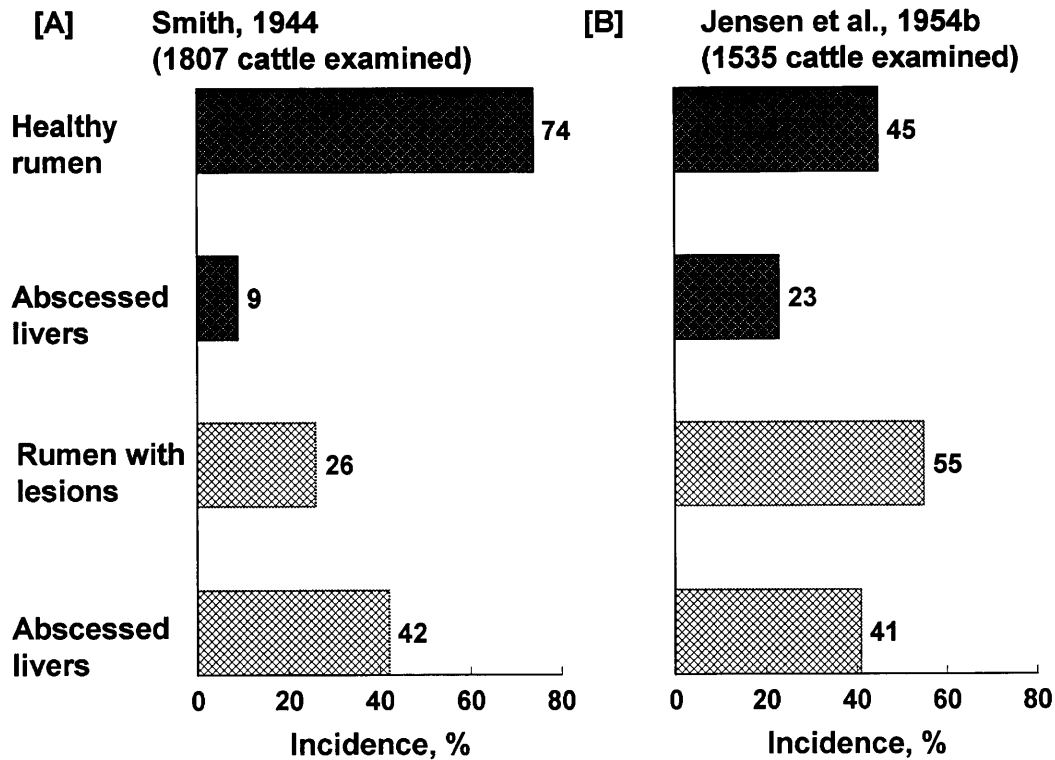


Figure 4. Relationship between ruminal lesions and liver abscesses in cattle.

and other dietary indiscretions such as a change in feeding patterns, allowing cattle to become overly hungry, feeding unpalatable diets, and feeding very little roughage (Elam, 1976). The ruminal damage often is aggravated by foreign objects in the feed, sharp feed particles, or hair (Jensen et al., 1954c; Fell et al., 1972).

The ruminal wall that is damaged from acidity or penetration of foreign objects becomes susceptible to invasion and colonization by *F. necrophorum*. After colonization has occurred, *F. necrophorum* can gain entry into the blood or cause ruminal wall abscesses and subsequently shed bacterial emboli to the portal circulation. Bacteria from the portal circulation are filtered by the liver, leading to infection and abscess formation (Figure 5).

Undoubtedly, the virulence factors of *F. necrophorum* play a critical role in the penetration and colonization of the ruminal epithelium and entry and establishment of infection in the liver. The protease activity, dermonecrotic activity, and cytotoxic effect of leukotoxin on ruminal cells may aid in penetration and colonization of the ruminal wall. The liver is a highly vascular, therefore richly oxygenated, and a highly defended organ because of its numerous phagocytic cells (leukocytes and Kupffer cells). Therefore, *F. necrophorum*, being an anaerobe, has to overcome both high oxygen concentrations and phagocytic mechanisms in order to survive, proliferate, and initiate abscess formation. The leukotoxin and endo-

toxic lipopolysaccharide of *F. necrophorum* may protect it from phagocytosis (Emery et al., 1986a,b; Tan et al., 1996). Also, the release of cytolytic products such as lysosomal enzymes and oxygen metabolites, as a consequence of destruction of phagocytes, has a detrimental effect on the liver parenchyma. Synergism with facultative bacteria (Roberts, 1967a,b; Takeuchi et al., 1983), intravascular coagulation induced by endotoxic lipopolysaccharide and platelet aggregation factor, formation of fibrin-encapsulated abscesses (Forrester et al., 1985), and impairment of oxygen transport by damaged erythrocytes (action of hemolysin) all may contribute to the establishment of an anaerobic microenvironment conducive to the growth of anaerobic bacteria within the ruminal wall and liver.

Diagnosis

Liver abscesses are detected only at the time of slaughter, because cattle, even those that carry hundreds of small abscesses or several large abscesses, seldom exhibit any clinical signs. Occasionally, cattle may exhibit abdominal pain, or the rupture of a superficial abscess or erosion and perforation of the caudal vena cava could lead to extensive spread and massive infection of other organs and death (Rubarth, 1960). Generally, hematology and liver function tests are not reliable indicators of liver

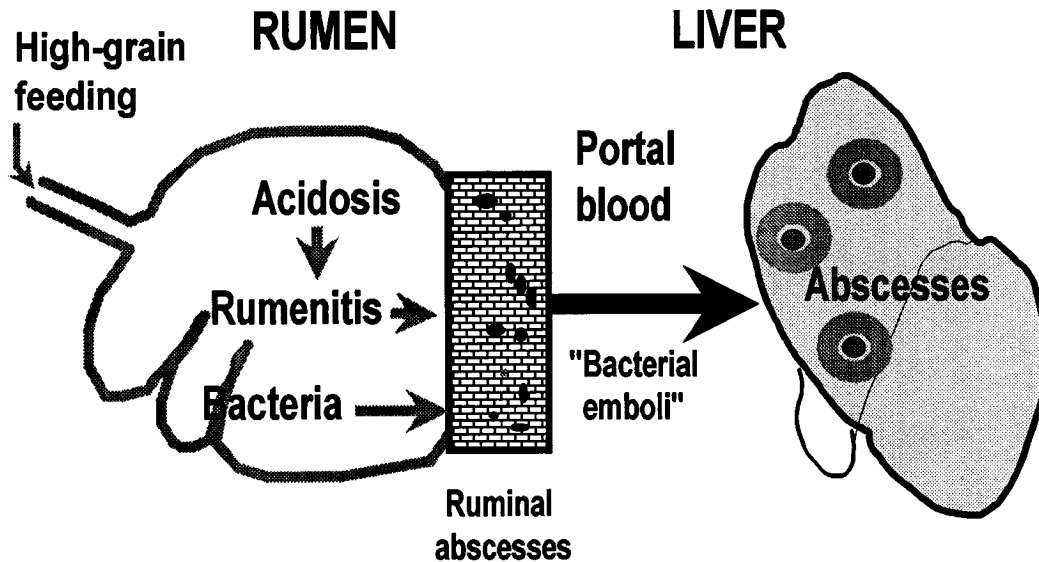


Figure 5. Pathogenesis of liver abscesses in cattle fed a high-grain diet.

abscesses (Haltenius and Jacobson, 1966; El Sabban et al., 1971). In instances where abscesses were induced by experimental inoculation of *F. necrophorum*, hepatic dysfunction has been documented by elevated serum protein, bilirubin, and enzymes such as γ -glutamyltransferase and sorbitol dehydrogenase concentrations (Scanlan and Berg, 1986; Itabisashi et al., 1987a; Lechtenberg and Nagaraja, 1991).

Ultrasonography, an imaging technique that permits visualization of soft tissues of internal organs, has been tested for liver abscess detection (Itabisashi et al., 1987b; Lechtenberg and Nagaraja, 1991). The liver is an ideal organ for ultrasonographic imaging because of its location and tissue consistency. The usefulness of the technique for diagnosis of various liver abnormalities including abscesses in small animals has been well documented (Wrigly, 1985). Ultrasonography is a useful technique for monitoring the onset and progression of experimentally induced abscesses when the site of injection is known. However, its application in feedlot cattle with naturally developed abscesses is limited; the ultrasonographic scanning cannot visualize the whole liver, particularly the left side facing the internal organs; also, parts of lobes are covered by other organs such as the lungs and kidneys.

Prevention

Antimicrobial Feed Additives. The control of liver abscesses in feedlot cattle generally has depended on the use of antimicrobial compounds. The antimicrobial sensitivity of *F. necrophorum* has been studied extensively (Shigidi, 1977; Simon, 1977; Berg and Scanlan, 1982; Baba et al., 1989; Lechtenberg and Nagaraja,

1989; Tan et al., 1994b). In general, *F. necrophorum* is susceptible to penicillins, tetracyclines, and macrolides but resistant to aminoglycosides and ionophore antibiotics (Baba et al., 1989; Lechtenberg and Nagaraja, 1989). This susceptibility to penicillins and macrolides and resistance to aminoglycosides is surprising, because the cell wall architecture of *F. necrophorum* is typical of Gram-negative bacteria (Garcia et al., 1992). Susceptibility or resistance to antibiotics do not differ between the two subspecies (Lechtenberg and Nagaraja, 1989; Tan et al., 1994b). The susceptibility pattern of *A. pyogenes* (the second most common organism in liver abscesses) to antimicrobial compounds is typical of Gram-positive bacteria (Specht et al., 1988).

According to the U.S. Feed Additive Compendium (1997), five antibiotics (bacitracin methylene disalicylate, chlortetracycline, oxytetracycline, tylosin, and virginiamycin) are approved for prevention of liver abscesses in feedlot cattle. These antibiotics differ in their inhibitory effect on *F. necrophorum* and *A. pyogenes* (Table 3) and their effectiveness in preventing liver abscesses (Matsushima et al., 1954; Flint and Jensen, 1958; Dinusson et al., 1964; Haskins et al., 1967; Brown et al., 1973, 1975; Potter et al., 1985; Vogel and Laudert, 1994; Rogers et al., 1995). Bacitracin is the least effective and tylosin is the most effective of the five antibiotics; however, the minimum inhibitory concentrations of these antibiotics, except for bacitracin, do not seem to be related to their efficacy (Haskins et al., 1967; Brown et al., 1973; Rogers et al., 1995). In addition to reduction in liver abscesses, feeding of certain antimicrobial compounds will improve weight gain and feed efficiency (Potter et al., 1985; Rogers et al., 1995). Inclusion of ionophore antibiotics such as monensin, lasalocid, or laidlomycin

Table 4. Liver abscess control and feedlot performance of tylosin- and non-tylosin-fed cattle^a

Item	Control	Tylosin-fed	% Improvement
No. of pens	266	279	—
No. of cattle	3,271	3,700	—
Average days on feed	134	134	—
Liver abscess, %	27.9	.5 ^b	73.1
DM intake, kg	8.72	8.72	—
Daily gain, kg	1.29	1.32 ^b	2.3
Feed/gain	6.90	6.72 ^b	2.6
Dressing percentage	61.65	61.80 ^b	.2

^aVogel and Laudert, 1994.

^bDiffers from control ($P < .01$).

propionate has had no effect on abscess incidence in several studies (Berger et al., 1981; Potter et al., 1985; Tan et al., 1994a; Bauer et al., 1995). Several studies have confirmed that the reduction in abscess incidence from tylosin feeding is 40 to 70% (Brown et al., 1975; Heinemann et al., 1978; Pendlum et al., 1978; Brink et al., 1990; Bartle and Preston, 1991; Tan et al., 1994a). A summary of 40 trials involving a total of 6,971 cattle from all major cattle feeding areas of the United States showed that tylosin (11 g/metric ton of air dry feed or 90 mg-animal⁻¹.d⁻¹) feeding reduced the incidence of liver abscesses by 73% (Vogel and Laudert, 1994). Cattle fed tylosin gained 2.1% faster, converted feed to gain 2.6% more efficiently, and yielded a slightly higher dressing percentage than the cattle fed no tylosin (Table 4).

The mode of action of tylosin is believed to be its inhibitory effect on *F. necrophorum*. Tylosin, a macrolide, is effective primarily against Gram-positive bacteria, but the Gram-negative *F. necrophorum* also is sensitive (Berg and Scanlan, 1982; Lechtenberg and Nagaraja, 1989; Tan et al., 1994b). The inhibitory effect of tylosin on *F. necrophorum* may be in the rumen, the liver, or both. Although tylosin is partially absorbed from the gut (Gingerich et al., 1977) and could reach the liver, it is believed to exert its primary effect in the rumen. Dietary inclusion of tylosin has been shown to prevent the increase in ruminal populations of *F. necrophorum* associated with feeding high-grain diets (Nagaraja et al., 1996c).

In addition to the inclusion of antimicrobial compounds in the feed, proper bunk management to minimize ruminal imbalance is well accepted as a key factor for effective control of liver abscesses. Some of the recommendations include adapting cattle to high-grain diets gradually, avoiding either under- or overfeeding, providing feed at several times per day to spread intake, increasing roughage content of the feed, imposing quality control in mixing feeds, and providing adequate bunk space and fresh, clean water (Jensen et al., 1954b; Elam, 1976; Hale, 1985; Bartle and Preston, 1991). Regulatory restrictions on the number of feed additives that can be legally incorpo-

rated into the feed have encouraged some to use intermittent feeding (3, 5, or 7 d/mo) of high level (.5 to 2 g-animal⁻¹.d⁻¹) of chlortetracycline or oxytetracycline. However, benefits from such short-term, high-level feeding of antibiotics have not been documented.

Vaccine. Antimicrobial compounds reduce the incidence of liver abscesses but do not eliminate the problem. Therefore, an effective vaccine would be highly desirable in the feedlot industry. The vaccine approach also would alleviate public health concerns associated with the use of subtherapeutic levels of antibiotics in the feed. Although the pathogenicity and virulence factors of *F. necrophorum* have been studied widely for many years, attempts to develop an effective vaccine against liver abscess have not been successful commercially.

Serum antibodies against *F. necrophorum* antigens have been detected in healthy and infected animals (Feldman et al., 1936; Simon and Stovell, 1969; Tan et al., 1994a). Several investigators have attempted to induce protective immunity against *F. necrophorum* by using a variety of antigenic components. Attempts to induce protective immunity have included the use of whole-cell cultures (Roberts, 1970; Abe et al., 1976a; Cameron and Fuls, 1977; Conlon et al., 1977; Smith et al., 1985, 1989), cytoplasmic fractions (Garcia et al., 1974, 1975a; Garcia and McKay, 1978), lipopolysaccharides (Garcia et al., 1974, 1975a; Abe et al., 1976a; Cameron and Fuls, 1977; Conlon et al., 1977; Smith et al., 1985, 1989), outer membrane proteins (Emery and Vaughn, 1986), leukotoxins (Roberts, 1970; Garcia et al., 1975a; Clarke et al., 1986; Emery et al., 1986a,b; Saginala et al., 1996a,b), and culture supernatants (Jensen et al., 1954c; Takeuchi et al., 1984; Saginala et al., 1996a,b, 1997). Efficacy has varied from nil to significant protection.

Because leukotoxin is considered to be the primary virulence factor involved in the onset of liver abscesses, immunity directed against leukotoxin may be

Table 3. Minimal inhibitory concentrations of antimicrobial feed additives for *Fusobacterium necrophorum* and *Actinomyces pyogenes* isolated from liver abscesses

Antimicrobial feed additives ^a	<i>Fusobacterium necrophorum</i> ^b	<i>Actinomyces pyogenes</i> ^c
Bacitracin	100.0	13.4
Chlortetracycline	.2	9.9
Oxytetracycline	.2	11.5
Tylosin	9.6	16.4
Virginiamycin	3.3	1.4
Lasalocid	87.5	1.3
Monensin	69.0	.5

^aIU/mL for bacitracin and µg/mL for all others.

^bAdapted from Lechtenberg and Nagaraja (1989) and Tan et al. (1994b).

^cNagaraja et al., 1993.

Table 5. Efficacy of *Fusobacterium necrophorum* leukotoxoid vaccine against experimentally induced liver abscesses in steers^{a,b}

Experiment and treatment	No. of steers	Incidence of liver abscesses	
		No. of steers positive	%
Saginala et al., 1996b			
Control	5	5	100
Vaccinated	5	0	0
Saginala et al., 1996a			
Control	5	3	60
Vaccinated	25	8	32
Saginala et al., 1997			
Control	5	0	100
Vaccinated	20	5	25

^aVaccine consisted of culture supernatant from a high-leukotoxin producing strain of *F. necrophorum* containing inactivated leukotoxin mixed with an adjuvant. Two injections were given subcutaneously at 3-wk intervals.

^bLiver abscesses were induced by intraportal injection of *F. necrophorum*.

related to protection. Leukotoxin of *F. necrophorum*, an exotoxin, is a high-molecular weight (> 300,000) protein (Tan et al., 1994d); therefore, it is strongly immunogenic (Tan et al., 1994a). Garcia et al. (1974) were able to reduce the incidence of liver abscesses from 35 to 10% by immunization with a toxoid prepared from the cytoplasmic fraction of *F. necrophorum*. The cytoplasmic toxoid possibly contained leukotoxin. Clarke et al. (1986) reported that cattle injected with *F. necrophorum* culture supernatant containing leukotoxin had a lower incidence of foot rot

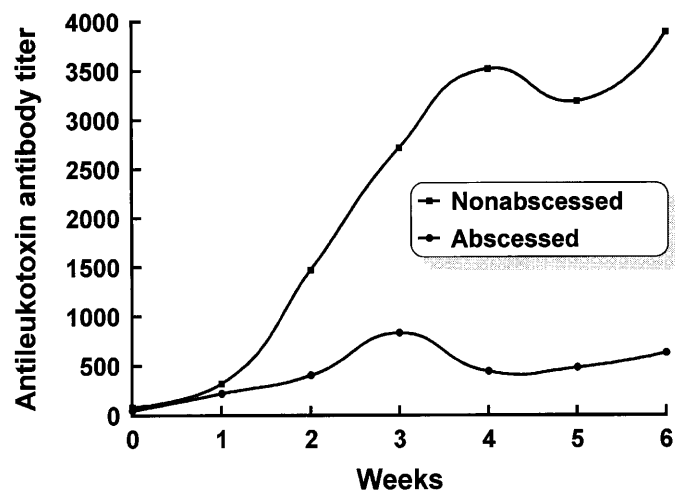


Figure 6. Serum antileukotoxin antibody titers following vaccination with *Fusobacterium necrophorum* leukotoxoid vaccine in steers that did or did not develop liver abscesses in response to intraportal challenge with *F. necrophorum* (Saginala et al., 1996a).

caused by *F. necrophorum*. Cell-free culture supernatant of a high leukotoxin producing strain of *F. necrophorum* (Tan et al., 1992), mixed with a suitable adjuvant, has been shown to elicit a high antileukotoxin antibody titer when injected in steers and provided significant protection to experimentally induced liver abscesses (Table 5; Saginala et al., 1996a,b, 1997). In such experimental challenge studies, the relationship between serum antileukotoxin antibody titers and protection was shown by lower antibody titers following vaccination for steers that developed liver abscesses than for those that did not (Figure 6). Further studies involving commercial feedlot cattle are needed to assess the benefit of a leukotoxoid vaccine to control liver abscesses.

Implications

Liver abscesses in feedlot cattle have a major economic impact in the beef industry because of liver condemnation and reduced animal performance and carcass yield. Prevention has largely involved the use of antimicrobial feed additives, particularly tylosin. A vaccine approach to control the problem may prove to be a preferable option.

Literature Cited

- Aalbaek, B. 1971. *Sphaerophorus necrophorus*: A study of 23 strains. Acta Vet. Scand. 12:344-364.
- Abe, P. M., E. S. Lennard, and J. W. Holland. 1976a. *Fusobacterium necrophorum* infection in mice as a model for the study of liver abscess formation and induction of immunity. Infect. Immun. 13:1473-1478.
- Abe, P. M., J. A. Majeski, and E. S. Lennard. 1976b. Pathological changes produced by *Fusobacterium necrophorum* in experimental infection of mice. J. Comp. Pathol. 86:365-369.
- Amoako, K. K., Y. Goto, and T. Shinjo. 1993. Comparison of extracellular enzymes of *Fusobacterium necrophorum* subspecies *necrophorum* and *Fusobacterium necrophorum* subspecies *funduliforme*. J. Clin. Microbiol. 31:2244-2247.
- Amoako, K. K., Y. Goto, and T. Shinjo. 1994. Studies on the factors affecting the hemolytic activity of *Fusobacterium necrophorum*. Vet. Microbiol. 41:11-18.
- Baba, E., T. Fukata, A. Arakawa, H. Ikawa, and M. Takeda. 1989. Antibiotic susceptibility of *Fusobacterium necrophorum* from bovine hepatic abscesses. Br. Vet. J. 145:195-197.
- Bartle, S. J., and R. L. Preston. 1991. Dietary roughage regimen for feedlot steers: Reduced roughage level (2%) during the mid-finishing period. J. Anim. Sci. 69:3461-3466.
- Bauer, M. L., D. W. Herald, R. A. Britton, R. A. Stock, T. J. Klopfenstein, and D. A. Yates. 1995. Efficacy of laidlomycin propionate to reduce ruminal acidosis in cattle. J. Anim. Sci. 73:3445-3454.
- Berg, J. N., and C. M. Scanlan. 1982. Studies of *Fusobacterium necrophorum* from bovine hepatic abscesses: Biotypes, quantitation, virulence, and antibiotic susceptibility. Am. J. Vet. Res. 43:1580-1586.
- Berger, L. L., S. C. Ricke, and G. C. Fahey, Jr. 1981. Comparison of two forms and two levels of lasalocid with monensin on feedlot cattle performance. J. Anim. Sci. 53:1440-1445.
- Brent, B. E. 1976. Relationship of acidosis to other feedlot ailments. J. Anim. Sci. 43:930-935.

- Brink, D. R., S. R. Lowry, R. A. Stock, and J. C. Parrott. 1990. Severity of liver abscesses and efficiency of feed utilization of feedlot cattle. *J. Anim. Sci.* 68:1201-1207.
- Brook, I., and R. I. Walker. 1986. The relationship between *Fusobacterium* species and other flora in mixed infection. *J. Med. Microbiol.* 21:93-100.
- Brown, H., R. F. Bing, H. P. Grueter, J. W. McAskill, C. O. Cooley, and R. P. Rathmacher. 1975. Tylosin and chlortetracycline for the prevention of liver abscesses, improved weight gains and feed efficiency in feedlot cattle. *J. Anim. Sci.* 40:207-213.
- Brown, H., N. G. Elliston, J. W. McAskill, O. A. Muenster, and L. V. Tonkinson. 1973. Tylosin phosphate (TP) and tylosin urea adduct (TUA) for the prevention of liver abscesses, improved weight gains and feed efficiency in feedlot cattle. *J. Anim. Sci.* 37:1085-1091.
- Calkins, H. E., and M. L. Dewey. 1968. Quantitative analysis of the microflora of a bovine liver abscess. *J. Bacteriol.* 94:1439-1440.
- Calkins, H. E., and L. H. Scrivner. 1967. Isolation of *Sphaerophorus necrophorus* from bovine liver abscesses. *Appl. Microbiol.* 15:1492-1493.
- Cameron, C. M., and W.J.P. Fuls. 1977. Failure to induce in rabbits effective immunity to a mixed infection of *Fusobacterium necrophorum* and *Corynebacterium pyogenes* with a combined bacterin Onderstepoort. *J. Vet. Res.* 44:253-256.
- Clarke, B. L., D. L. Emery, D. J. Stewart, J. H. Duffy, and D. A. Anderson. 1986. Studies into immunization of cattle against interdigital necrobacillosis in cattle. *Aust. Vet. J.* 62:47-49.
- Conlon, P. J., K. P. Hepper, and G. W. Teresa. 1977. Evaluation of experimentally induced *Fusobacterium necrophorum* infections in mice. *Infect. Immun.* 15:510-517.
- Coyle-Dennis, J. E., and L. H. Lauerman. 1978. Biological and chemical characteristics of *Fusobacterium necrophorum* leukotoxin. *Am. J. Vet. Res.* 39:1790-1793.
- Coyle-Dennis, J. E., and L.H. Lauerman. 1979. Correlations between leukocidin production and virulence of two isolates of *Fusobacterium necrophorum*. *Am. J. Vet. Res.* 40:274-276.
- Dehaan, L. L., S. C. Rick, G. C. Fahey, Jr., and M. L. Gibson. 1995. The effect of age, background and gender on feed intake by feedlot cattle. In: Symposium: Intake by feedlot cattle. pp 9-22. Oklahoma State University, Stillwater.
- Dinsson, W. E., C. N. Hauge, D. O. Erickson, and M. L. Buchanan. 1964. Hi-moisture barley in hi-energy beef rations. *J. Anim. Sci.* 23:873 (Abstr.).
- El Sabban, F. F., H. Rothenbacher, T. A. Long, and B. R. Baumgardt. 1971. Certain blood constituents and serum transaminases in Hereford steers fed high-energy rations. *Am. J. Vet. Res.* 32:1027-1032.
- Elam, C. J. 1976. Acidosis in feedlot cattle: Practical observations. *J. Anim. Sci.* 43:898-901.
- Emery, D. L. 1989. Antigenes of *Fusobacterium necrophorum*. In: J. R. Egerton, W. K. Yong, and G. G. Riffkin (Ed.) Footrot and Foot Abscess of Ruminants. pp 135-140. CRC Press, Boca Raton, FL.
- Emery, D. L., R. D. Edwards, and J. S. Rothel. 1986a. Studies on the purification of the leukocidin of *Fusobacterium necrophorum* and its neutralization by specific antisera. *Vet. Microbiol.* 11:357-372.
- Emery, D. L., and J. A. Vaughan. 1986. Generation of immunity against *Fusobacterium necrophorum* or mice inoculated with extracts containing leukotoxin. *Vet. Microbiol.* 12:255-268.
- Emery, D. L., J. A. Vaughan, B. L. Clark, J. H. Dufty, and D. J. Stewart. 1985. Cultural characteristics and virulence of strains of *Fusobacterium necrophorum* isolated from the feet of cattle and sheep. *Aust. Vet. J.* 62:43-46.
- Emery, D. L., J. A. Vaughan, B. L. Clark, and D. J. Stewart. 1986b. Virulence determinants of *Fusobacterium necrophorum* and their prophylactic potential in animals. In: D. J. Stewart, J. E. Peterson, N. M. McKern, and D. L. Emery (Ed.) Footrot in Ruminants. pp 267-274. CSIRO Division of Animal Health, Australian Wool Corporation, Australia.
- Feed Additive Compendium. 1997. The Miller Publishing Co., Minnetonka, MN.
- Feldman, W. H., H. R. Hester, and F. P. Wherry. 1936. The occurrence of *Bacillus necrophorus* agglutinins in different species of animals. *J. Infect. Dis.* 59:159-170.
- Fell, B. F., M. Kay, E. R. Ørskov, and R. Boyne. 1972. The role of ingested animal hairs and plant spicules in the pathogenesis of rumenitis. *Res. Vet. Sci.* 13:30-36.
- Fiévez, L. 1963. Étude comparée des souches de *Sphaerophorus necrophorus* isolées chez l'homme et chez l'animal. Presses Académiques Européennes, Brussels.
- Flint, J. C., and R. Jensen. 1958. The effect of chlortetracycline fed continuously during fattening on the incidence of liver abscesses in beef cattle. *Am. J. Vet. Res.* 19:830-832.
- Forrester, L. J., B. J. Campbell, J. N. Berg, and J. T. Barrett. 1985. Aggregation of platelets by *Fusobacterium necrophorum*. *J. Clin. Microbiol.* 22:245-249.
- Foster, L., and W. R. Wood. 1970. Liver losses in finishing cattle. Nebraska Beef Cattle Report, University of Nebraska, Lincoln. pp 2-4.
- Fulton, W. R., T. J. Klopfenstein, and R. A. Britton. 1979. Adaptation to high concentrate diets by beef cattle. II. Effect of ruminal pH alteration on rumen fermentation and voluntary intake of wheat diets. *J. Anim. Sci.* 49:785-789.
- Garcia, M. M., D. C. Alexander, and K. A. McKay. 1975a. Biological characterization of *Fusobacterium necrophorum* cell fractions in preparation for toxin and immunization studies. *Infect. Immun.* 11:609-611.
- Garcia, M. M., S.A.W.E. Becker, B. W. Brooks, J. N. Berg, and S. M. Finegold. 1992. Ultrastructure and molecular characterization of *Fusobacterium necrophorum* biovars. *Can. J. Vet. Res.* 56:318-325.
- Garcia, M. M., K. M. Charlton, and K. A. McKay. 1975b. Characterization of endotoxin from *Fusobacterium necrophorum*. *Infect. Immun.* 11:371-379.
- Garcia, M. M., W. J. Dorward, D. C. Alexander, S. E. Magwood, and K. A. McKay. 1974. Results of a preliminary trial with *Sphaerophorus necrophorus* toxoids to control liver abscesses in feedlot cattle. *Can. J. Comp. Med.* 38:222-226.
- Garcia, M. M., and K. A. McKay. 1978. Intraperitoneal immunization against necrobacillosis in experimental animals. *Can. J. Comp. Med.* 42:121-127.
- Garcia, M. M., D. H. Neil, and K. A. McKay. 1971. Application of immunofluorescence to studies on the ecology of *Sphaerophorus necrophorus*. *Appl. Microbiol.* 21:809-814.
- Gill, D. R., F. N. Owens, R. W. Fent, and R. K. Fulton. 1979. Thiopeptin and roughage level for feedlot steers. *J. Anim. Sci.* 49:1145-1150.
- Gingerich, D. A., J. D. Baggot, and J. J. Kowalski. 1977. Tylosin antimicrobial activity and pharmacokinetics in cows. *Can. Vet. J.* 18:96-100.
- Hale, W. H. 1985. Liver abscesses and founder. *Anim. Nutr. Health* Sept: 12-20.
- Haltenius, P., and S. O. Jacobson. 1966. Ornithine-carbamyl transferase (OCT) activity in ruminants. *Cornell Vet.* 45:187-195.
- Harman, B. R., M. H. Brinkman, M. P. Hoffman, and H. L. Self. 1989. Factors affecting in-transit shrink and liver abscesses in fed steers. *J. Anim. Sci.* 67:311-317.
- Harvey, R. W., M. B. Wise, T. N. Blumer, and E. R. Barrick. 1968. Influence of added roughage and chlortetracycline to all-concentrate rations for fattening steers. *J. Anim. Sci.* 27:1438-1444.
- Haskins, B. R., M. B. Wise, H. B. Craig, and E. R. Barrick. 1967. Effects of levels of protein, sources of protein and an antibiotic on performance, carcass characteristics, rumen environment and liver abscesses of steers fed all-concentrate rations. *J. Anim. Sci.* 26:430-434.
- Heinemann, W. W., E. M. Hanks, and D. C. Young. 1978. Monensin and tylosin in a high energy diet for finishing steers. *J. Anim. Sci.* 47:34-40.

- Hicks, R. B., F. N. Owens, D. R. Gill, J. W. Oltjen, and R. P. Lake. 1994. Daily dry matter intake by feedlot cattle: Influence of breed and gender. *J. Anim. Sci.* 68:245-253.
- Hussein, H. E., and M.T.A. Shigedi. 1974. Isolation of *Sphaerophorus necrophorus* from bovine liver abscesses in the Sudan. *Trop. Anim. Health Prod.* 6:253-254.
- Inoue, T., M. Kanoe, N. Goto, K. Matsumura, and K. Nakano. 1985. Chemical and biological properties of lipopolysaccharides from *Fusobacterium necrophorum* biovar A and biovar B strains. *Jpn. J. Vet. Sci.* 47:639-645.
- Itabisashi, T., K. Tamiya, R. Yamamoto, and M. Satoh. 1987a. Serum sialic acid levels in cattle inoculated with *Fusobacterium necrophorum*. *Jpn. J. Vet. Sci.* 49:673-680.
- Itabisashi, T., R. Yamamoto, and M. Satoh. 1987b. Ultrasonogram of hepatic abscesses in cattle inoculated with *Fusobacterium necrophorum*. *Jpn. J. Vet. Sci.* 49:585-592.
- Jensen, R., W. E. Connell, and A. W. Deem. 1954a. Rumenitis and its relation to rate of change of ration and the proportion of concentrate in the ration of cattle. *Am. J. Vet. Res.* 15:425-428.
- Jensen, R., H. M. Deane, L. J. Cooper, V. A. Miller, and W. R. Graham. 1954b. The rumenitis-liver abscess complex in beef cattle. *Am. J. Vet. Res.* 15:202-216.
- Jensen, R., J. C. Flint, and L. A. Griner. 1954c. Experimental hepatic necrobacillosis in beef cattle. *Am. J. Vet. Res.* 15:5-14.
- Kanoe, M., K. Abe, K. Kai, and H. Blobel. 1995. Dermonecrotic activity of a cell wall preparation from *Fusobacterium necrophorum*. *Lett. Appl. Microbiol.* 20:145-147.
- Kanoe, M., H. Imagawa, M. Toda, A. Sata, and M. Inoue. 1976. Bacteriology of bovine hepatic abscesses. *Jpn. J. Vet. Sci.* 38:263-268.
- Kanoe, M., and K. Iwaki. 1986. Adherence of *Fusobacterium necrophorum* to bovine hepatic cells. *FEMS Microbiol. Lett.* 35:245-248.
- Kanoe, M., and K. Iwaki. 1987. Adherence of *Fusobacterium necrophorum* to bovine ruminal cells. *J. Med. Microbiol.* 23:69-73.
- Kanoe, M., Y. Izuchi, M. Kemi, M. Toda, and Y. Hara. 1979. Hepatic abscess in fattened dairy steers. *Jpn. J. Vet. Sci.* 41:73-76.
- Kanoe, M., Y. Izuchi, and M. Toda. 1978. Isolation of *Fusobacterium necrophorum* from bovine ruminal lesions. *Jpn. J. Vet. Sci.* 40:275-281.
- Kanoe, M., N. Kitamoto, M. Toda, and K. Uchida. 1984. Purification and partial characterization of *Fusobacterium necrophorum* haemolysin. *FEMS Microbiol. Lett.* 25:237-242.
- Kanoe, M., and M. Yamanaka. 1989. Bovine platelet aggregation by *Fusobacterium necrophorum*. *J. Med. Microbiol.* 29:13-17.
- Kreikemeier, K. K., D. L. Harmon, R. T. Brandt, Jr., T. G. Nagaraja, and R. C. Cochran. 1990. Steam-rolled wheat diets for finishing cattle: Effects of dietary roughage and feed intake on finishing steer performance and ruminal metabolism. *J. Anim. Sci.* 68:2130-2141.
- Ladely, S. R., R. A. Stock, F. K. Goedeken, and R. P. Huffman. 1995. Effect of corn hybrid and grain processing method on rate of starch disappearance and performance of finishing cattle. *J. Anim. Sci.* 73:360-364.
- Langworth, B. F. 1977. *Fusobacterium necrophorum*: Its characteristics and role as an animal pathogen. *Bacteriol. Rev.* 41:373-390.
- Lechtenberg, K. L., and T. G. Nagaraja. 1989. Antimicrobial sensitivity of *Fusobacterium necrophorum* isolates from bovine hepatic abscesses. *J. Anim. Sci.* 67(Suppl. 1):544 (Abstr.).
- Lechtenberg, K. F., and T. G. Nagaraja. 1991. Hepatic ultrasonography and blood changes in steers with experimentally induced liver abscesses. *Am. J. Vet. Res.* 52:803-809.
- Lechtenberg, K. F., T. G. Nagaraja, H. W. Leipold, and M. M. Chengappa. 1988. Bacteriologic and histologic studies of hepatic abscesses in cattle. *Am. J. Vet. Res.* 49:58-62.
- Mader, T. L., J. M. Dahlquist, R. A. Britton, and V. E. Krause. 1991a. Type and mixture of high-moisture corn in beef cattle finishing diets. *J. Anim. Sci.* 69:3480-3486.
- Mader, T. L., J. M. Dahlquist, and L. D. Schmidt. 1991b. Roughage sources in beef cattle finishing diets. *J. Anim. Sci.* 69:462-471.
- Mader, T. L., G. L. Poppert, and R. A. Stock. 1993. Evaluation of alfalfa type as a roughage source in feedlot adaptation and finishing diets containing different corn types. *Anim. Feed Sci. Technol.* 42:109-119.
- Madin, S. H. 1949. A bacteriologic study of bovine liver abscesses. *Vet. Med.* 44:248-251.
- Matsushima, J., T. W. Dowe, and C. H. Adams. 1954. Effect of aureomycin in preventing liver abscesses in cattle. *Proc. Soc. Exp. Biol. Med.* 85:18-20.
- Miyazato, S., T. Shinjo, H. Yago, and N. Nakamura. 1978. Fimbriae (pili) detected in *Fusobacterium necrophorum*. *Jpn. J. Vet. Sci.* 40:619-621.
- Montgomery, T. H. 1985. The influence of liver abscesses upon beef carcass yields. Special Technical Bulletin. West Texas State University, Canyon.
- Montgomery, T. H. 1992. Improving the consistency and competitiveness of beef. National Beef Quality Audit—1991. pp 144-147. National Cattlemen's Association, Denver, CO.
- Nagai, S., M. Kanoe, and M. Toda. 1984. Purification and partial characterization of *Fusobacterium necrophorum* hemagglutinin. *Zentralbl. Bakteriolog. Hyg. A.* 258:232-241.
- Nagaraja, T. G., A. B. Beharka, M. M. Chengappa, L. H. Carroll, A. P. Raun, S. B. Laudert, and J. C. Parrott. 1993. Bacterial flora of liver abscesses from feedlot cattle fed tylosin or no tylosin. *J. Anim. Sci.* 71(Suppl. 1):278 (Abstr.).
- Nagaraja, T. G., S. B. Laudert, and J. C. Parrott. 1996a. Liver abscesses in feedlot cattle. Part 1. Causes, pathogenesis, pathology and diagnosis. *Comp. Cont. Edu. Pract. Vet.* 18:S230-S256.
- Nagaraja, T. G., S. B. Laudert, and J. C. Parrott. 1996b. Liver abscesses in feedlot cattle. Part 2. Incidence, economic importance and prevention. *Comp. Cont. Edu. Pract. Vet.* 18:S264-S273.
- Nagaraja, T. G., N. Wallace, Y. Sun, K. E. Kemp, and J. C. Parrott. 1996c. Effect of dietary tylosin on *Fusobacterium necrophorum* population in the rumen of cattle fed high-grain diet. *J. Anim. Sci.* 74(Suppl. 1):81 (Abstr.).
- Nakagaki, M., M. Fukuchi, and M. Kanoe. 1991. Partial characterization of *Fusobacterium necrophorum* protease. *Microbios.* 66:117-123.
- Nakajima, Y., H. Ueda, Y. Yagi, K. Nakamura, Y. Motoi, and S. Takeuchi. 1986. Hepatic lesions in cattle caused by experimental infection of *Fusobacterium necrophorum*. *Jpn. J. Vet. Sci.* 48:509-515.
- National Beef Quality Audit Report. 1995. National Cattlemen's Association, Denver, CO.
- Newsom, I. E. 1938. A bacteriologic study of liver abscesses in cattle. *J. Infect. Dis.* 63:232-233.
- Nicholson, L. A., C. J. Morrow, L. A. Corner, and A.L.M. Hodgson. 1994. Phylogenetic relationship of *Fusobacterium necrophorum* A, AB, and B biotypes based upon 16s rRNA gene sequence analysis. *Int. J. Syst. Bacteriol.* 44:315-319.
- Pendulum, L. C., J. A. Boling, and N. W. Bradley. 1978. Levels of monensin with and without tylosin for growing-finishing steers. *J. Anim. Sci.* 47:1-5.
- Potter, E. L., M. I. Wray, R. D. Muller, H. P. Grueter, J. McAskill, and C. Young. 1985. Effect of monensin and tylosin on average daily gain, feed efficiency and liver abscess incidence in feedlot cattle. *J. Anim. Sci.* 61:1058-1065.
- Roberts, D. S. 1967a. The pathogenic synergy of *Fusiformis necrophorus* and *Corynebacterium pyogenes*. I. Influence of the leukocidal exotoxin of *F. necrophorus*. *Br. J. Exp. Pathol.* 48:665-673.
- Roberts, D. S. 1967b. The pathogenic synergy of *Fusiformis necrophorus* and *Corynebacterium pyogenes*. II. The response of *F. necrophorus* to a filterable product of *C. pyogenes*. *Br. J. Exp. Pathol.* 48:674-679.
- Roberts, D. S. 1970. Toxic, allergenic and immunogenic factors of *Fusiformis necrophorus*. *J. Comp. Pathol.* 80:247-257.

- Robinson, T. J., D. E. Jasper, and H. R. Guilbert. 1951. The isolation of *Spherophorus necrophorus* from the rumen together with some feed lot data on abscess and telangiectasis. *J. Anim. Sci.* 10:733-741.
- Rogers, J. A., M. E. Branine, C. R. Miller, M. I. Wray, S. J. Bartle, R. L. Preston, D. R. Gill, R. H. Pritchard, R. P. Stilborn, and D. T. Bechtol. 1995. Effects of dietary virginiamycin on performance and liver abscess incidence in feedlot cattle. *J. Anim. Sci.* 73:9-20.
- Rubarth, S. 1960. Hepatic and subphrenic abscesses in cattle with rupture into the vena cava. *Acta Vet. Scand.* 1:1363-1382.
- Saginala, S., T. G. Nagaraja, K. F. Lechtenberg, M. M. Chengappa, K. E. Kemp, and P. M. Hine. 1997. Effect of *Fusobacterium necrophorum* leukotoxoid vaccine on susceptibility to experimentally induced liver abscesses. *J. Anim. Sci.* 75:1160-1166.
- Saginala, S., T. G. Nagaraja, Z. L. Tan, K. F. Lechtenberg, M. M. Chengappa, and P. M. Hine. 1996a. Serum neutralizing antibody response to *Fusobacterium necrophorum* leukotoxoid, and protection against experimentally induced hepatic abscesses. *Vet. Res. Commun.* 20:493-504.
- Saginala, S., T. G. Nagaraja, Z. L. Tan, K. F. Lechtenberg, M. M. Chengappa, K. E. Kemp, and P. M. Hine. 1996b. Serum neutralizing antibody response and protection against experimentally induced abscesses in steers vaccinated with *Fusobacterium necrophorum*. *Am. J. Vet. Res.* 57:483-488.
- Scanlan, C. M., and J. N. Berg. 1986. Comparative changes in a rat liver abscess model induced with three *Fusobacterium necrophorum* strains. *Am. J. Vet. Res.* 47:924-927.
- Scanlan, C. M., J. N. Berg, and W. H. Fales. 1986. Comparative in vitro leukotoxin production of three bovine strains of *Fusobacterium necrophorum*. *Am. J. Vet. Res.* 43:1329-1333.
- Scanlan, C. M., and T. L. Hathcock. 1983. Bovine rumenitis-liver abscess complex: A bacteriological review. *Cornell Vet.* 73:288-297.
- Shigidi, M.T.A. 1977. Susceptibility of *Sphaerophorus necrophorus* isolated from cattle in the Sudan to chemotherapeutic agents. *Br. Vet. J.* 131:356-360.
- Shinjo, T., T. Fujisawa, and T. Mitsuoka. 1991. Proposal of two subspecies of *Fusobacterium necrophorum* (Flügge) Moore and Holdeman: *Fusobacterium necrophorum* subsp. *necrophorum* subsp. nov., nom. rev. (ex Flügge 1886), and *Fusobacterium necrophorum* subsp. *funduliforme* subsp. nov., nom. rev. (ex Hallé 1898). *Int. J. Syst. Bacteriol.* 41:395-397.
- Shinjo, T., K. Hiraiwa, and S. Miyazato. 1990. Recognition of biovar C of *Fusobacterium necrophorum* (Flügge) Moore and Holdeman as *Fusobacterium pseudonecrophorum* sp. nov., nom. rev. (ex Prévot 1940). *Int. J. Syst. Bacteriol.* 40:71-73.
- Shinjo, T., and H. Kiyoyama. 1986. Pathogenicity of a non-hemagglutinating mutant strain of *Fusobacterium necrophorum* biovar A in mice. *Jpn. J. Vet. Sci.* 48:523-527.
- Simon, P. C. 1977. Susceptibility of *Fusobacterium necrophorum* to antimicrobials part I: as determined by the disc method. *Can. J. Comp. Med.* 41:166-168.
- Simon, P. C., and P. L. Stovell. 1969. Diseases of animals associated with *Sphaerophorus necrophorus*. *Vet. Bull.* 39:311-315.
- Simon, P. C., and P. L. Stovell. 1971. Isolation of *Sphaerophorus necrophorus* from bovine hepatic abscesses in British Columbia. *Can. J. Comp. Med.* 35:103-106.
- Smith, G. R., A. Turner, L. G. Murray, and J. C. Oliphant. 1985. The weak immunogenicity of *Fusobacterium necrophorum*. *J. Hyg. (Cambr.)* 95:59-68.
- Smith, G. R., L. Wallace, M. Wallace, and D. Till. 1989. Necrobacillosis and immunity in mice. *Epidemiol. Infect.* 103:211-215.
- Smith, H. A. 1944. Ulcerative lesions of the bovine rumen and their possible relation to hepatic abscesses. *Am. J. Vet. Res.* 5:234-242.
- Specht, H., W. Gedek, and G. Dirksen. 1988. Minimum inhibitory concentrations of different antibiotics for *Pasteurella multocida*, *Pasteurella haemolytica* and *Corynebacterium pyogenes* of bovine origin and therapeutic considerations. *Bovine Pract.* 23:35-41.
- Stock, R. A., D. R. Brink, R. T. Brandt, J. K. Merrill, and K. K. Smith. 1987. Feeding combinations of high moisture corn and dry corn to finishing cattle. *J. Anim. Sci.* 65:282-289.
- Stock, R. A., M. H. Sindt, R. M. Cleale, IV, and R. A. Britton. 1991. High-moisture corn utilization in finishing cattle. *J. Anim. Sci.* 69:1645-1656.
- Stock, R. A., M. H. Sindt, J. C. Parrott, and F. K. Goedecken. 1990. Effects of grain type, roughage level and monensin level on finishing cattle performance. *J. Anim. Sci.* 68:3441-3455.
- Takeuchi, S., Y. Nakajima, and K. Hashimoto. 1983. Pathogenic synergism of *Fusobacterium necrophorum* and other bacteria in formation of liver abscess in BALB/c mice. *Jpn. J. Vet. Sci.* 45:775-781.
- Takeuchi, S., Y. Nakajima, J. Ueda, Y. Motoi, Y. Kobayashi, and T. Morozumi. 1984. Hepatic abscess formation in cattle inoculated with *Fusobacterium necrophorum*. *Jpn. J. Vet. Sci.* 46:339-344.
- Tan, Z. L., K. F. Lechtenberg, T. G. Nagaraja, M. M. Chengappa, and R. T. Brandt, Jr. 1994a. Serum neutralizing antibodies against *Fusobacterium necrophorum* leukotoxin in cattle with experimentally induced or naturally developed hepatic abscesses. *J. Anim. Sci.* 72:502-508.
- Tan, Z. L., T. G. Nagaraja, and M. M. Chengappa. 1992. Factors affecting the leukotoxin activity of *Fusobacterium necrophorum*. *Vet. Microbiol.* 32:15-28.
- Tan, Z. L., T. G. Nagaraja, and M. M. Chengappa. 1994b. Biochemical and biological characterization of ruminal *Fusobacterium necrophorum*. *FEMS Microbiol. Lett.* 120:81-86.
- Tan, Z. L., T. G. Nagaraja, and M. M. Chengappa. 1994c. Selective enumeration of *Fusobacterium necrophorum* from the bovine rumen. *Appl. Environ. Microbiol.* 60:1387-1389.
- Tan, Z. L., T. G. Nagaraja, and M. M. Chengappa. 1996. *Fusobacterium necrophorum* infections: virulence factors, pathogenic mechanism and control measures. *Vet. Res. Commun.* 20:113-140.
- Tan, Z. L., T. G. Nagaraja, M. M. Chengappa, and J. S. Smith. 1994d. Biological and biochemical characterization of *Fusobacterium necrophorum*. *Am. J. Vet. Res.* 55:515-521.
- Utley, P. R., R. E. Hellwig, J. L. Butler, and W. C. McCormick. 1973. Comparison of unground, ground and pelleted peanut hulls as roughage sources in steer finishing diets. *J. Anim. Sci.* 37:608-611.
- Vogel, G. J., and S. B. Laudert. 1994. The influence of Tylan® on liver abscess control and animal performance—A 40 Trial Summary. *J. Anim. Sci.* 72(Suppl. 1):293 (Abstr.).
- Vogel, G. J., and J. C. Parrott. 1994. Mortality survey in feedyards: The incidence of death from digestive, respiratory, and other causes in feedyards on the Great Plains. *Comp. Cont. Edu. Pract. Vet.* 16:227-234.
- Wada, E. 1978. Studies on *Fusobacterium* species in the rumen of cattle. I. Isolation of genus *Fusobacterium* from rumen juice of cattle. *Jpn. J. Vet. Sci.* 40:435-439.
- Warner, J. F., W. H. Fales, R. C. Sutherland, and G. W. Teresa. 1975. Endotoxin from *Fusobacterium necrophorum*. *Infect. Immun.* 11:371-379.
- Wieser, M. F., T. R. Preston, A. Macdearmid, and A. C. Rowland. 1966. Intensive beef production 8. The effect of chlortetracycline on growth, feed utilization and incidence of liver abscesses in barley beef cattle. *Anim. Prod.* 8:411-423.
- Wrigley, R. H. 1985. Radiographic and ultrasonographic diagnosis of liver diseases in dogs and cats. *Vet. Clin. North Am. Small Anim. Pract.* 15:21-38.
- Yamamoto, S. 1938. Multiple liver abscesses in cattle caused by necrosis bacillus. *J. Jpn. Soc. Vet. Sci.* 17:40-49.
- Zinn, R. A., and A. Plascencia. 1996. Effects of forage level on the comparative feeding value of supplemental fat in growing-finishing diets for feedlot cattle. *J. Anim. Sci.* 74:1194-1201.